

Original Article

CASE SERIES OF INFECTIOUS RETINITIS : A 2 YEAR REVIEW IN HOSPITAL SELAYANG

Mahani Mastor^{*1,2}, Azian Adnan¹, Amelia Lim Lay Suan¹, Hanizasurana Hashim¹

¹Department of Ophthalmology, Hospital Selayang

²Department of Ophthalmology Hospital Universiti Kebangsaan Malaysia

ARTICLE INFO

Corresponding author:
Dr. Mahani Mastor

Email address:
mahanibintimastor@yahoo.com

Received:
May 2018
Accepted for publication:
June 2018

Keywords:

Infectious retinitis
Immunocompromised
Immunocompetent

ABSTRACT

In Malaysia and globally, infectious diseases remain a complicated and never-ending series of problems affecting multiorgan and system including the eyes. Retinitis as a consequence of infection is potentially sight threatening and occurs in both immunocompetent and immunocompromised individuals. Retinitis may affect human in eye per se or often as a manifestation of systemic illness. A total of 24 patients and 31 eyes were included in this retrospective electronic observational case series review. Only cases with positive history and clinical findings together with positive laboratory findings in Hospital Selayang from 2015 until 2017 were analysed. We excluded Retroviral cases as they may have multifactorial cause of immunodeficiency as a result of opportunistic infections. Our target is to identify common cause of infectious retinitis in immunocompetent and immunocompromised patients hence can offer good treatment and prevent blindness. In the future we plan to extend period of our study to include more cases of infectious retinitis besides to compare differences between those groups.

INTRODUCTION

Retinitis as a consequence of infection is potentially sight threatening and can occur in both immunocompetent and immunocompromised individuals. Infectious retinitis is caused by different types of pathogens including viruses, bacteria, fungi or parasites. The symptoms include floaters, blurring of vision and eye discomfort. The clinical signs are anterior uveitis, vitritis, yellow plaque-like lesion, with some may have vasculitis and choroiditis. Retinal detachment and retinal atrophy may complicate infectious retinitis if not treated accordingly.

MATERIALS AND METHODS

A total of 24 patients and 31 cases from January 2015 until December 2017 were studied. All these data were extracted electronically using the keywords ' Retinitis, Infectious, immunocompetent, and immunocompromised'. The cases were reviewed individually from the first presentation, symptoms, clinical findings, diagnosis and treatment. Only those with positive serology findings were chosen and included in this study. Subsequently those data were classified into immunocompetent and immunocompromised groups

and the number of the causative agents were calculated. Vision of each patient was also analysed.

RESULTS

The patients involved in this study aged between 8 and 77 years old. The mean age group is 28years old. The causes of infectious retinitis varies in causative agents (Figure 1) with Bartonella (Figure 2) being the highest, 54%, viral causes namely Cytomegalovirus (Figure 3) accounts for 12.5% and Varicella Zoster Virus 8.5% while Leptospira, Burkholderia Pseudomallei (Figure 4), Tuberculosis and Toxoplasma (Figure 5) accounts for 4.1% respectively.

Immunocompetent patients who developed retinitis occurred in 21patients (87.5%) and in immunosuppressed, 3 patients (12.5%) (Figure 6). Patients in immunosuppressed group are patients with malignancy who underwent chemotherapy and those with autoimmune disease on immunosuppressant drugs. Bartonella is the most common cause of retinitis in immunocompetent patients (54%). In contrast Cytomegalovirus retinitis

Infectious Retinitis Caused by Different Pathogens

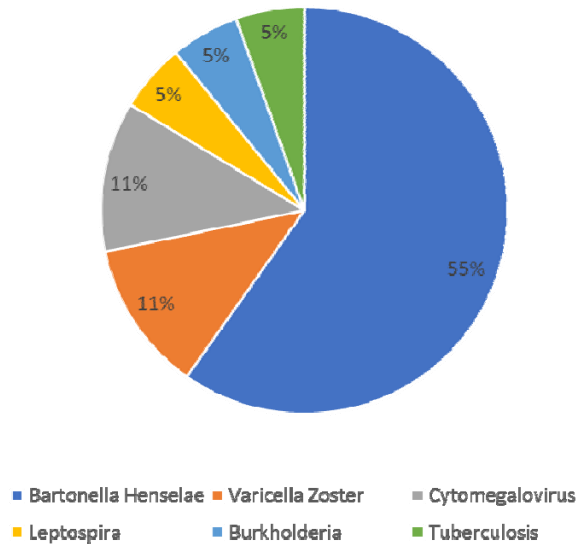


Figure 1: Pie chart of different causative agents of Infectious retinitis

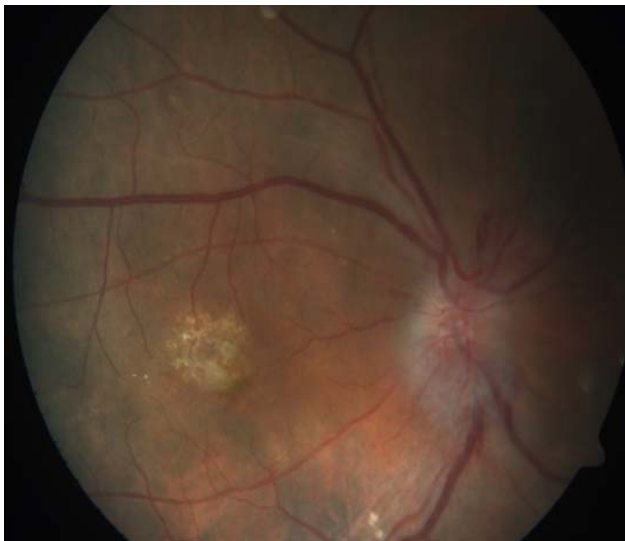

Figure 2: Fundus photograph of patient with Neuroretinitis secondary Bartonella infection.

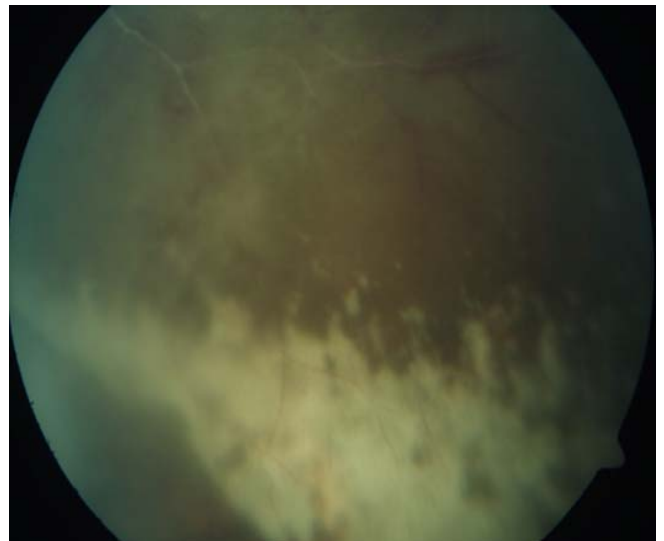

Figure 3: Fundus photograph of patient with Cytomegalovirus retinitis.

(11.11%) is the cause seen in 3 immunosuppressed patients.

All patients received treatment accordingly with complete resolution of the lesion. However final visual outcome varies among patients. In immunocompetent group 38% of the patients gain vision of $\geq 6/9$ and another 62% has vision which ranges from 6/18 to Counting Fingers at a distance of 3feet. All the 3 patients in the immunosuppressed group had vision < Counting Fingers. Macula scar, epiretinal

membrane and lamella hole are the main causes of poor vision in both group.

DISCUSSION

Bartonellosis is the commonest cause of infectious retinitis seen in these case series which probably due to geographical factor as a tropical country [1,2]. Bartonella Henselae which is a gram negative rod infects human via traumatic contact or by vectors

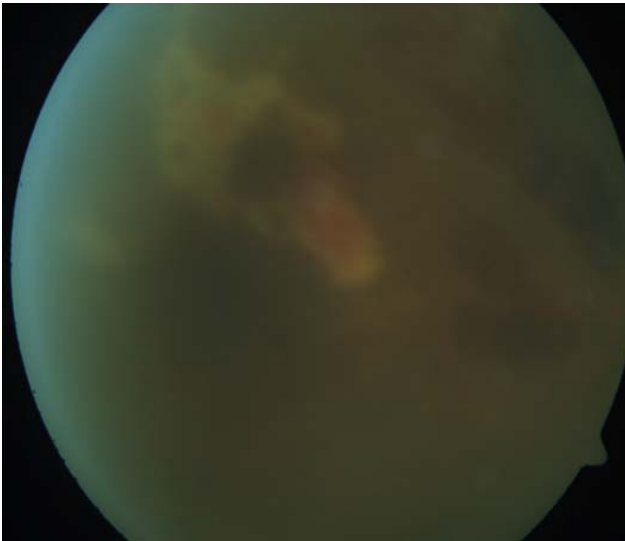


Figure 4: Fundus photograph of patient with Melioidosis.

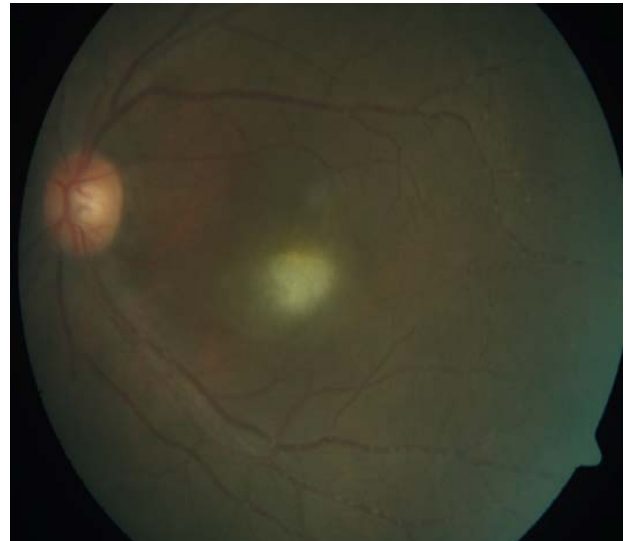


Figure 5: Fundus photograph of patient with Toxoplasma Retinitis

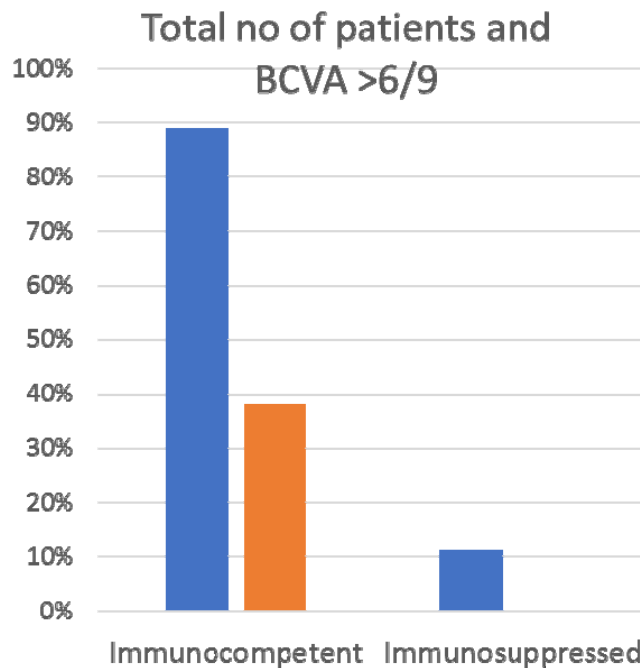


Figure 6 : Total no of patients in immunocompetent group is 90% and Immunosuppressed group 10%. 38% of immunocompetent group gained vision $\geq 6/9$ and none in immunosuppressed group has vision $> 6/9$

like cat flea, mosquitoes or sand fly. It makes a protein binder, adheres to red blood cells, penetrate into endothelial cell and colonise there. Therefore immunocompetent individual is also vulnerable to the disease. Besides retinitis or neuroretinitis, it causes various ocular manifestation such as conjunctivitis, focal chorioretinitis, subretinal fluid and vasculitis. Tuberculosis is still endemic in Malaysia. It is 1 of the most infectious disease with rates of incidence of 79.8 per 100000 [3]. It may present with large variations of clinical presentation including vitritis, vasculitis, and

retinitis. Thus, it is a great mimicker and must be ruled out in all suspected infectious case. Cytomegalovirus in immunocompetent patients are not well documented [4]. It frequently reported in immunocompromised patients such as transplant recipient and HIV positive patient. However a study by Dowling et al [5] revealed that 8 of 14 patients receiving immunosuppressive drugs infected with Cytomegalovirus systemically. Cytomegalovirus causes full-thickness retinal necrosis with pathognomonic cytomegalic cells with intranuclear

inclusions. *Leptospira* and *Burkholderia sp*, are not to be missed out during investigating cause of retinitis. Clinical examinations and laboratory diagnostics are mandatory for diagnosis and successful treatment. Likewise knowledge of the immune status of the host is essential since immune modifying strategies may be needed to complement the anti infective treatment in those patients who have been on immunosuppressant drugs.

CONCLUSION

Infectious retinitis can occur regardless immune status of a host. Bartonella is the commonest cause but mainly among immunocompetent individuals whereby Cytomegalovirus in immunocompromised group. Early diagnosis and aggressive treatment are crucial to prevent debilitating visual complications.

REFERENCES

1. Cunningham ET, Koehler JE. Am J Ophthalmol. 2000 Sep;130(3):340-9
2. Bartonella species in small mammals and their potential vectors in Asia Oct 2014. Asian Pacific Journal of Tropical Biomedicine. Volume 4, Issue 10, October 2014, Pages 757-767
3. http://www.moh.gov.sg/content/moh_web/home/publications/Reports/2016/communicable-diseases-surveillance-in-Singapore-2015.html
4. T-G wreghitt E.L Teen Osule_Clinical infectious disease, Volume 37, Issue 12, 15Dec2003 page 1603-1606.
5. Dowling et al J infect Dis 1976 Cytomegalovirus infection in patients receiving immunosuppressive drugs.