The International Journal of Medicine and Sciences ***5*** *(1) 2020 : 49-52*

Case Report

LATE RETINAL REDETACHMENT SECONDARY TO PROLIFERATIVE VITREORETINOPATHY

Izwan Kamal Tan*[1], Mushawiahti M[1], Ropilah Abdul Rahman[2]

[1]Department of Ophthalmology, Faculty of Medicine, University Kebangsaan Malaysia Medical Centre, Jalan Yaacob Latif, Bandar Tun Razak, 56000 Kuala Lumpur, Malaysia.
[2]Kulliyyah of Medicine & Health Sciences, Universiti Islam Antarabangsa Sultan Abdul Halim Mua'dzam Shah, 09300 Kuala Ketil, Kedah, Malaysia.

ARTICLE INFO

Corresponding author:
Dr. Izwan Kamal Tan

Email address:
izwankamaltan@yahoo.co.uk

Received:
May 2020
Accepted for publication:
June 2020

Keywords:
Retinal detachment
proliferative vitreoretinopathy
late onset retinal re-detachment

ABSTRACT

This report is to highlight that retinal redetachment may occur late, a decade after a previously successful re-attachment surgery and the need to inform patients of this consequence. A 44-year-old Malay lady presented with an inferior field defect in her left eye for one week. Her left best corrected visual acuity was 6/18 and N18 for near. She was myopic with history of retinal detachment surgery twelve years previously. She was found to have superior retinal detachment and break due to late onset proliferative vitreoretinopathy (PVR). She underwent a successful re-attachment surgery. The need to counsel patients following retinal detachment surgery is necessary. They should be made aware of the symptoms of redetachment due to late onset PVR.

INTRODUCTION

Proliferative vitreoretinopathy (PVR) is defined as a complex healing process that involves multiple cellular proliferations. The cellular proliferations occur on the inner and outer retinal surfaces, or both, and on vitreous strands which then contract [1]. It can occur prior to surgical repair or develop post-operatively causing either recurrent retinal detachment due to new breaks, or existing retinal breaks [2]. Clinically, PVR is seen as a variety of different intraocular cellular proliferations including epiretinal membranes, subretinal strands, and retinal detachments in combination with star folds, vitreous traction, and anterior loop traction or anterior PVR [3].

The incidence of PVR varies from 4%-34% following primary vitrectomy in rhegmatogenous retinal detachment [3]. It is by far the most common and significant cause of delayed failure of primary retinal detachment surgery which results in poor visual outcome [4].

Following vitreoretinal surgery PVR is generally noted to occur between 2 weeks to 45 months. Statistically, 79% of PVR develops within the first 3 months, and 90% within the first 6 months [3]. The calculated median time intervals between onset of retinal disease and primary PVR as well as the time intervals between surgery for PVR and the recurrences is noted to be two months [3].

Our case is an uncommon case of delayed onset PVR that resulted in retinal redetachment, as it occured more than 10 years after the primary reattachment surgeries. This emphasize the importance of patient counselling regarding the symptoms of retinal redetachment and the need for immediate consultation.

CASE REPORT

A 44-year-old Malay lady, a known myope, had left pars planar vitrectomy with gas performed for rhegmatogenous retinal detachment (RRD) in February 2001. She developed redetachment a month following the surgery for which another surgery was performed with sulphur hexafluoride (SF6) gas tamponade. She recovered well. in April 2003 she underwent an uneventful phacoemulsification with intraocular lens implantation. Post cataract surgery her retinal remained flat. Her post-operative BCVA was 6/18. She then continued to be on regular follow-up at 6 to 9 monthly intervals for the next 10 years.

She presented to the Eye Casualty in July 2013 with complaint of reduced inferior visual field of 1 week's duration. At presentation then her left BCVA was 6/18, N18. The inferior visual field defect progressed

upward and left visual acuity progressively deteriorated to hand movement within a week. Clinically there was superior RRD involving the macula. There were multiple small retinal holes in the peripheral retina superiorly. Examination revealed the presence of Proliferative vitreoretinopathy Grade B (Figure 1).

The patient underwent pars planar vitrectomy with retinotomy and drainage, heavy liquid fluid exchange, endolaser and SF6 20% gas as tamponade (Figure 2). Intraoperatively, internal search revealed that the original break had sealed, however there were new breaks in the superior nasal quadrant. There was localised PVR involving the superonasal retina with residual cortical vitreous causing retinal breaks and detachment. At 24 months following this surgery, the retina has remained flat. Her BCVA returned to 6/18.

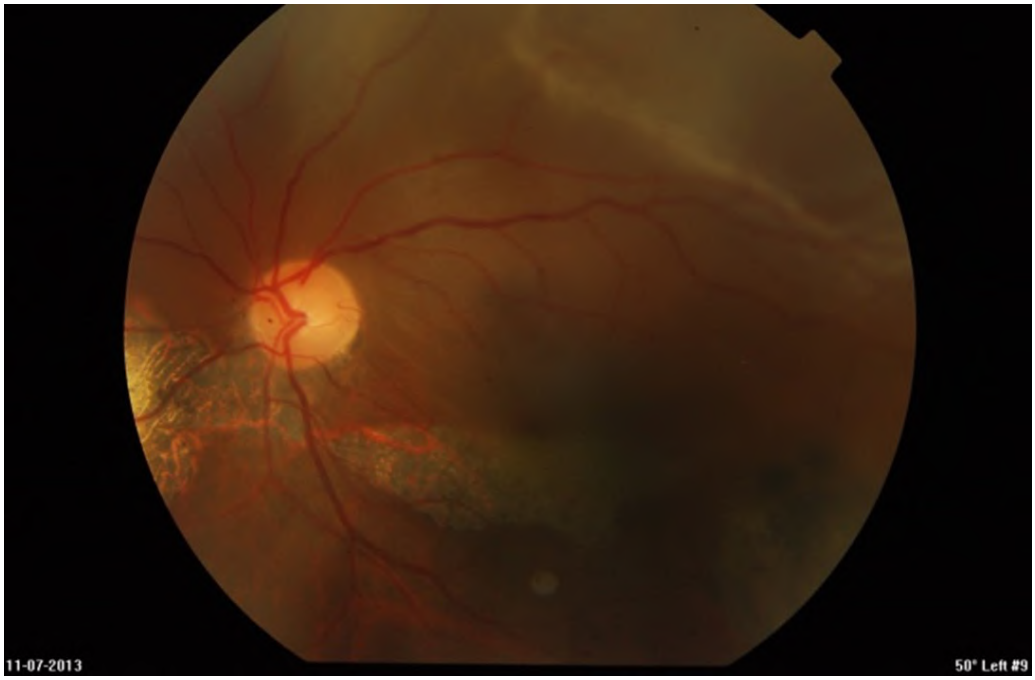

Figure 1: Left fundus photograph showing superior rhegmatogenous retinal detachment involving the macula

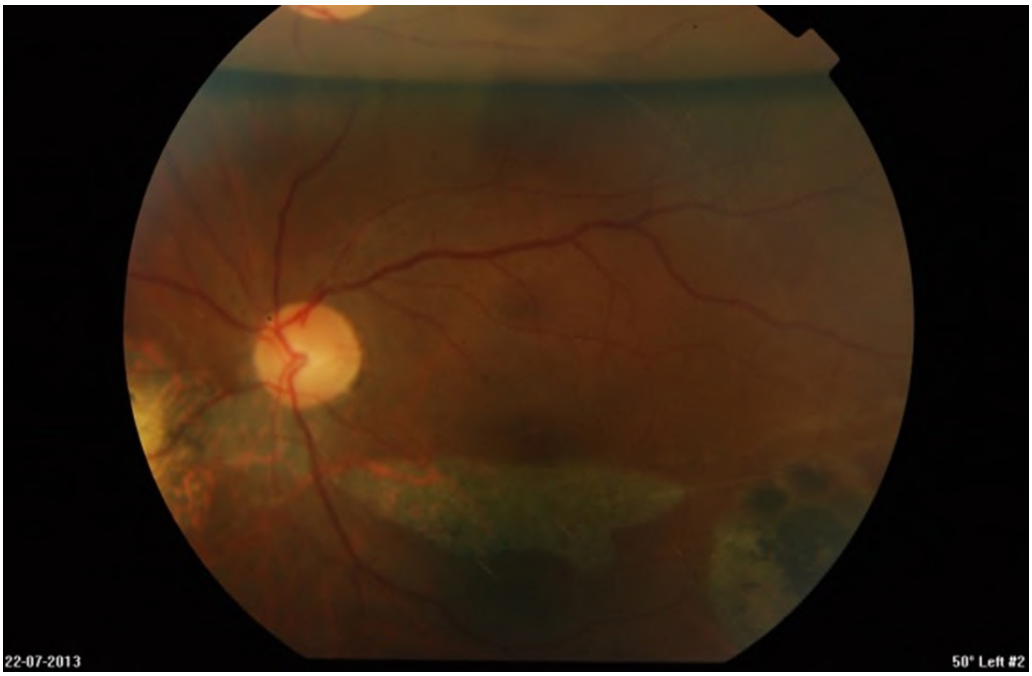

Figure 2: Left fundus photograph showing flat retina two weeks following the vitrectomy with residual gas tamponade superiorly

DISCUSSION

Mietz and Heimann investigated the mean time intervals between the retinal disease and the development of PVR and the time intervals at which recurrent PVR developed following various kinds of vitreoretinal diseases and surgery in 136 consecutive cases retrospectively [3]. The study found that the median time intervals between surgery and recurrence for the second, third or fourth time was two months, ranged between 0.5 – 34 months. They concluded that PVR starts earliest at two weeks after an event and subsequently quietens down within a maximum of 45 months and PVR may recur more than once.

Proliferative Vitreo-retinopathy may develop pre and post-operatively. Pre-operative risk factors include chronic retinal detachment, large and multiple retinal breaks and concurrent intraocular inflammation or hypoxia. Risk factors for post-operative development of PVR include retained or residual vitreous following the primary vitrectomy as found in our case, more likely in young individuals. Other risk factors include the presence of blood, liberal usage of cryotherapy, traumatic retinal detachment as in this case and persistent intraocular inflammation post-operatively [4].

Various methods have been attempted to overcome PVR including intraocular and systemic use of corticosteroids, anti-growth factor agents and autologous plasma used intra-operatively; however the results remain inconclusive [5]. The importance of thorough vitreous removal particularly during vitrectomy as well as the control of inflammation and bleeding to reduce the incidence of PVR cannot be over emphasized [6]. For instance, in this patient contraction of residual vitreous near the superonasal aspect of the vitreous base and a localised anterior PVR probably led to the late onset retinal tear and detachment. The location of the initial retinal tear which was near the location of the superonasal vitrectomy port, highlights the difficulty of viewing and removing vitreous in this location during the initial surgery and vitrectomy.

With the advance of surgical instrument and techniques, the success rate of reattachment has increased. Retinal reattachment can be achieved by different surgical approaches such as vitrectomy with internal tamponade or scleral buckling techniques. Various other methods of management have been suggested, ranging from the injection of additional silicone oil, to repeated membrane peeling with retinotomy. Anatomic success vary from 53% to 81%, in specific patient groups that were treated for recurrent retinal detachment.(7) Nonetheless, the visual results can be disappointing. Timely reoperation must be the key to retaining vision. Hence, the importance of patient education especially when the follow-up after the initial surgery would be many months apart or even yearly as illustrated by this case [8,9].

Of the treatment options for recurrent RRD, pars planar vitrectomy is the treatment of choice for retinal redetachment secondary to advanced stages of PVR, and may be performed in combination with scleral buckling or with retinectomy in such instances. Scleral buckling alone is limited to cases of mild PVR [8]. In eyes operated on with pars plana vitrectomy, the recurrence of RD after silicone oil (SO) removal ranged from 8.8 to 34% with almost 89% of incidences occurring within 1-3 months of removal of SO. Retinal detachment after SO removal is more commonly a complication of the early postoperative period and the retinal detachment most often involves the inferior retina [10].

The most important reasons for late failures are vitreous base traction and periretinal proliferations that clinically appear as new or reopened tears or as PVR as seen in our case. A more difficult or complex situation is often the case in most recurrent retinal detachment and generally require more extensive surgical interventions. Based on the anatomic and functional success rates, repeat surgical procedures are worth considering.

CONCLUSION

Recurrent retinal detachment in previously vitrectomised eyes varies between 8% and 34%, and occur usually within 5 months postoperatively. However, late onset redetachment may occur in a stable vitrectomised eye after many years. This case illustrates that PVR can still occur even after more than a decade. Regular long-term follow-up may not be practical nor economical for post-operative retinal detachment patients in general, thus it is highly recommended that all post-operative patients be counselled on possibility of late redetachment and be made aware of the symptoms to be anticipated.

REFERENCES

1. Norlelawati Z, Bastion MLC. Late Retinal Redetachment Due to Proliferative Vitreoretinopathy after More than One Decade, Journal of Surgical Academia 2016;6(2): 43-45
2. Leiderman YI, Miller JW. Proliferative vitreoretinopathy: pathobiology and therapeutic targets. Semin Ophthalmol 2009; 24(2): 62-9.
3. Mietz H, Heimann K. Onset and recurrence of proliferative vitreoretinopathy in various vitreoretinal diseases. Br J Ophthalmol 1995; 79 (10): 874-7.
4. Cardillo JA, Stout JT, LaBree L, et al. Post-traumatic proliferative vitreoretinopathy. The epidemiologic profile, onset, risk factors, and visual outcome. Ophthalmology 1997; 104(7): 1166-73.
5. Waters T, Vollmer L, Sowka J. Proliferative vitreoretinopathy as a late complication of blunt ocular trauma. Optometry 2008; 79(4): 197-202.

6. Charteris DG. Proliferative vitreoretinopathy: Pathobiology, surgical management, and adjunctive treatment. Br J Ophthalmol 1995; 79(10): 953–60.
7. Foster RE, Meyers SM. Recurrent retinal detachment more than 1 year after reattachment. Ophthalmology 2002; 109: 1821-7
8. Moysidis SN, Thanos A, Vavvas DG. Review article: mechanisms ofinflammation in proliferative vitreoretinopathy: from bench to bedside. Mediators Inflamm 2012; 2012: 815937.
9. Charteris DG, Sethi CS, Lewis GP, Fisher SK. Proliferative vitreoretinopathy-developments in adjunctive treatment and retinal pathology. Eye (Lond) 2002; 16(4): 369–74.
10. Pournaras C, Chrysanthi T, Brouzou C, Tsilimbaris MK. Surgical and Visual Outcome for Recurrent Retinal Detachment Surgery. Journal of Ophthalmology, 2014,Volume 2014 , Article ID 810609