

## Case Report

### SIXTH CRANIAL NERVE PALSY SECONDARY TO INDIRECT CAROTID CAVERNOUS FISTULA IN A PATIENT WITH RECENT COVID-19 VACCINATION

Bannu Jayallan<sup>\*1</sup>, Wan Asyraf<sup>2</sup>, Rozman Zakaria<sup>3</sup>, Mae-Lynn Catherine Bastion<sup>1</sup>

<sup>1</sup>Department of Ophthalmology, University Kebangsaan Malaysia Medical Centre, Jalan Yaacob Latif, Bandar Tun Razak, 56000 Kuala Lumpur, Malaysia.

<sup>2</sup>Department of Neurology, University Kebangsaan Malaysia Medical Centre, Jalan Yaacob Latif, Bandar Tun Razak, 56000 Kuala Lumpur, Malaysia.

<sup>3</sup>Department of Neurology, University Kebangsaan Malaysia Medical Centre, Jalan Yaacob Latif, Bandar Tun Razak, 56000 Kuala Lumpur, Malaysia.

#### ARTICLE INFO

Corresponding author:  
Dr. Bannu Jayallan

Email address:  
bannujayallan@gmail.com

Received:  
July 2022  
Accepted for publication:  
August 2022

#### Keywords:

sixth cranial nerve palsy;  
carotid cavernous fistula;  
diplopia;  
cerebral angiography

#### ABSTRACT

*Sixth cranial nerve palsy (SCNP) is a rare complication of carotid cavernous fistula (CCF), a malformation of vascular communication between the carotid artery and cavernous sinus. A 46-year-old female presented with diplopia. She also complained of intermittent headache, tinnitus and facial swelling 2 days after receiving COVID-19 Comirnaty (BNT162b2) vaccination. Visual acuity was 6/6 in both eyes. Extraocular muscle movements limitation was observed in levoversion, levelevation and levodepression. Diplopia worsens for near vision. Examination of the anterior segments, posterior segments and intraocular pressures were unremarkable. The cerebral angiogram revealed evidence of left indirect carotid- cavernous fistula, and embolization of the fistula was done. Two weeks post-procedure, diplopia resolved, and extraocular muscle was full. Neuroimaging is advisable in patients who develop SCNP with no significant vasculopathy risk factors as it helps to diagnose other life-threatening causes of the SCNP.*

#### INTRODUCTION

Sixth cranial nerve palsy (SCNP), also known as abducens nerve palsy, is a common clinical presentation seen in ophthalmology practice. Being the second longest cranial nerve it is vulnerable to various pathologies such as microischemic diseases, trauma, inflammatory conditions, multiple sclerosis, vasculopathy, viral infection, meningitis, tumours, nasopharyngeal carcinoma and raised intracranial pressure. Increased intracranial pressure is often accompanied by symptoms such as headache, diplopia and swollen optic discs. About 10% of nasopharyngeal carcinoma develops SCNP and presents with nasal stuffiness and epistaxis. A rare cause of SCNP is carotid-cavernous fistula (CCF). In CCF, SCNP is due to its location which is adjacent to the internal carotid artery (ICA) in the cavernous sinus [1]. Isolated SCNP following COVID-19 vaccination has also been previously reported [2]. Neuroimaging is usually indicated to investigate the cause of SCNP unless there is an apparent underlying medical condition. This case illustrates the importance of performing neuroimaging in a patient who developed SCNP after receiving COVID-19 vaccination.

#### CASE PRESENTATION

A 46-year-old female presented with diplopia on left gaze. In addition to diplopia, she also had an intermittent headache, tinnitus, and facial swelling. However, there was no vision loss, fever, nausea, vomiting, unilateral weakness or seizure. She denied any history of trauma. She did not have other underlying medical conditions. She received her first dose of COVID-19 vaccination two days prior to the presentation. She received the Comirnaty (BNT162b2) vaccination developed by Pfizer and BioNTech. On examination, she has a right face turn. Her best corrected visual acuity was 6/6 in both eyes. Extraocular muscle movements, namely levoversion, levo elevation and levo depression were limited in the left gaze. Diplopia was worse at near vision. Ocular examination of the anterior segments, intraocular pressures and fundi were unremarkable. Her optic disc was not swollen, and there were no corkscrew vessels seen in the conjunctiva. The Hess chart showed left SCNP with overaction of the right medial rectus muscle. All her vital signs were stable. There were no other neurological deficits.

Magnetic resonance imaging (MRI) revealed possible left CCF (Figure 1). The subsequent cerebral angiogram performed confirmed the left indirect CCF (Figure 2). The patient was advised to patch the left eye to overcome the diplopia while awaiting repair of the fistula. She was also prescribed oral vitamin B1, B6 and B12

supplements. Embolisation of the fistula was done using a catheter and coils immediately after the diagnosis was confirmed (Figure 2). Two weeks after the embolisation procedure, the patient's diplopia resolved, and her extraocular muscle movement was full.

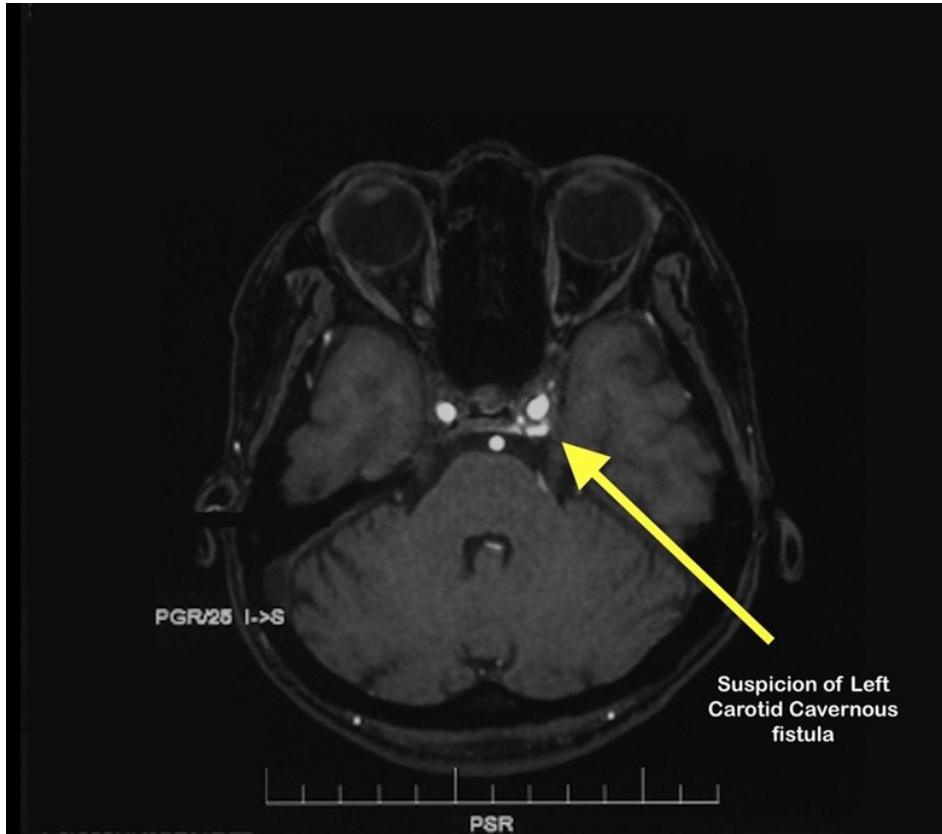


Figure 1: MRI brain showing axial cut at the level of cavernous sinus

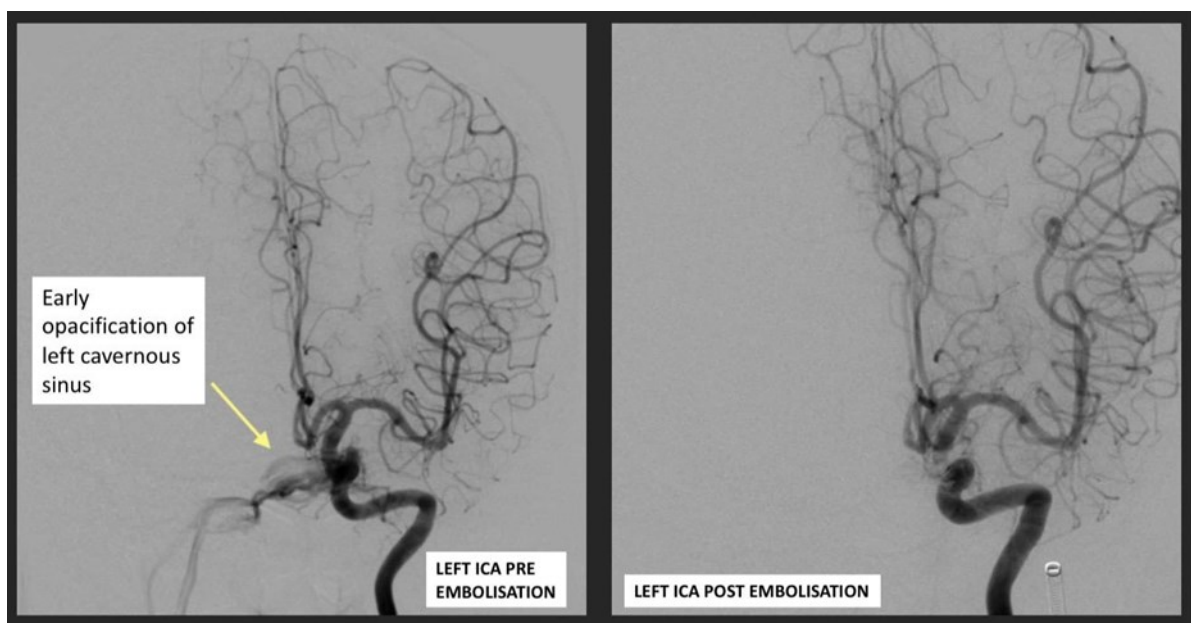


Figure 2: Cerebral angiography pre and post embolization

## DISCUSSION

The common cause for SCNP are ischemic microvascular causes such as diabetes mellitus, hypertension, hyperlipidaemia and coronary artery diseases. The recovery is usually spontaneous within three to six months and improves with time. A retrospective study among patients with microvascular ischemic SCNP found that 86% of patients had complete recovery during their follow up. Urgent neuroimaging is usually deferred in such cases as the symptoms are self-limiting with established vasculopathic risk factors [3, 4].

In addition to the ischemic microvascular causes, any insult to the brainstem, subarachnoid space, cavernous sinus or along the course of the sixth cranial nerve may lead to SCNP. Intracranial pathology would be the primary suspicion among patients presenting with sudden onset SCNP. The sixth nerve arises from the nucleus located in the dorsal pons, ventral to the floor of the fourth ventricle at the level of facial colliculus. The nerve fibre emerges from the nucleus through the pontomedullary groove and travels through the subarachnoid space. It crosses the upper edge of the tip of the petrous part of the temporal bone towards the clivus called Dorello's canal. It enters the dura mater inferior to the posterior clinoid process. Therefore, the nerve is prone to stretching when there is an increase in the intracranial pressure. It enters the cavernous sinus inferotemporal to the ICA and the orbit through the superior orbital fissure within the annulus of Zinn to the lateral rectus muscle. Hence, in CCF, the sixth cranial nerve can be affected [5].

Carotid-cavernous fistula is a malformation of the vascular communication between ICA, external carotid artery and cavernous sinus in the brain. It can be classified as direct or indirect and further divided according to the Barrow Classification. Indirect CCF is usually spontaneous and caused by a dural rupture in the arterial wall. Indirect CCF also has an association with hypertension, advanced age and a female predilection. On the contrary, trauma is the leading cause of direct CCF. Clinical signs of indirect CCF are usually milder than direct CCF, which have a more dramatic presentation. The usual clinical presentations of CCF are eye redness, diplopia, tearing, ocular foreign body sensation, blurring of vision, proptosis, tinnitus and headache. Eye redness is often characterised by arterialisation of the conjunctival vessels due to backpressure from the cavernous sinus which leads to tortuous and dilated conjunctival vessels, known as corkscrew vessels. Nonetheless, our patient presented with diplopia, tinnitus, facial swelling and intermittent headache. In a retrospective study, the commonest ophthalmic sign in CCF is proptosis (78.7%). Ocular nerve paresis was reported in 61.7% of patients, out of which 10.64% accounts for sixth nerve palsy [6, 7].

Since our patient presented with SCNP two days after receiving the first dose of Comirnaty COVID - 19 vaccination, the possible association of the

SCNP to the vaccination could not be ruled out until we perform the neuroimaging investigation. There is a reported case of SCNP as a possible neurological sequelae post Comirnaty COVID-19 vaccination [2]. Unlike our patient, their patient's neuroimaging was normal. The reports from US Vaccine Adverse Event Reporting System states that SCNP is the most common motor palsy following vaccinations [8].

The Comirnaty (BNT162b2) developed by Pfizer and BioNTech is an mRNA vaccine that encodes the S-2P protein. The nucleoside-modified RNA vaccine encodes a prefusion stabilised state and membrane-anchored SARS-CoV-2 full-length spike protein, allowing the host immune system to detect the virus before it enters the host cell. (9) The theory behind post immunisation neurological sequelae of SCNP is still not established. However, it is hypothesised as an immune-mediated effect by host antibodies that cross-react with proteins present in peripheral myelin, causing demyelination [2].

Neuroimaging confirmation is required in CCF [7]. Digital subtraction angiography (DSA) also known as cerebral angiography is the gold standard for CCF neuroimaging. It is able to demonstrate the arterial supply, flow rate, and venous drainage to identify the type of CCF. It has an additional therapeutic value in planning for endovascular treatment. A standard computed tomographic (CT) scan and magnetic resonance imaging (MRI) will not be able to establish the findings of CCF. However, it may reveal orbital congestion with enlargement of the extraocular muscles and dilated superior orbital vein, which leads to suspicion of CCF. A non-invasive computed tomographic angiography (CTA) or MRA yields a better diagnostic value in neuroimaging of CCF in comparison to the standard CT scan and MRI [7]. When there is a suggestive history and clinical findings with no known underlying medical condition as in our patient, neuroimaging is a valuable diagnostic tool to identify the cause of sixth nerve palsy.

In our patient, the cerebral angiogram was performed, and it confirmed the presence of left indirect CCF, ipsilateral to the SCNP. Therefore, active management was recommended to the patient. There are various treatment options for CCF, such as conservative management, surgical management, for example, surgical trapping of the fistula and transvenous surgical packing and endovascular treatment. Endovascular techniques using coils, silk and liquid embolic material (such as Onyx) or both can successfully repair the fistula, restore normal orbital venous drainage and establish intradural arterial flow. Embolisation of fistula has a favourable outcome in indirect CCF with an ocular presentation. Most of the ocular complaints resolve after treatment. In our patient, endovascular techniques using coils were performed. A total of four coils were inserted. Coils are easy to use and it has an advantage in the coil's position adjustment after insertion to ensure

successful embolization [10].

The complications of embolisation are; worsening of ophthalmoplegia, internal carotid artery occlusion, stroke, forehead dysaesthesia and superior orbital nerve damage due to exposure of the superior ophthalmic vein. The complication of embolisation was reported as low as 1% to as high as 40% [10]. In this patient, diplopia resolved after two weeks of embolization of left carotid cavernous fistula, which supported the diagnosis of indirect CCF as the cause of the SCNP.

## CONCLUSION

SCNP has many attributable pathologies which are usually benign. However, since the patient developed SCNP post COVID-19 vaccination, the possibility of SCNP as a neurological sequelae post vaccination should be considered. Urgent neuroimaging is advisable in such cases to aid the diagnosis of the underlying pathology causing the SCNP. Neuroimaging was crucial in our case to diagnose other life-threatening causes of SCNP such as CCF; which warrants immediate treatment. There are various treatment options to treat CCF. Nonetheless, embolisation of fistula using coils has one of the most favourable outcomes in CCF.

## REFERENCES

1. Margolin, E. Approach to patient with diplopia. *J Neurol Sci* **417**, 117055 (2020).
2. Reyes-Capo, D.P., Stevens, S.M. & Cavuoto, K.M. Acute abducens nerve palsy following COVID-19 vaccination. *J AAPOS* (2021).
3. Sanders, S.K., Kawasaki, A. & Purvin, V.A. Long-term prognosis in patients with vasculopathic sixth nerve palsy. *Am J Ophthalmol* **134**, 81-84 (2002).
4. Murchison, A.P., Gilbert, M.E. & Savino, P.J. Neuroimaging and acute ocular motor mononeuropathies: a prospective study. *Arch Ophthalmol* **129**, 301-305 (2011).
5. Lieber, S., Fernandez-Miranda, J.C. Anatomy of the Orbit. *J Neurol Surg B Skull Base* **81**, 319-332 (2020).
6. Grumann, A.J., Boivin-Faure, L., Chapot, R., Adenis, J.P. & Robert, P.Y. Ophthalmologic outcome of direct and indirect carotid cavernous fistulas. *Int Ophthalmol* **32**, 153-159 (2012).
7. Henderson, A.D. & Miller, N.R. Carotid-cavernous fistula: current concepts in aetiology, investigation, and management. *Eye (Lond)* **32**, 164-172 (2018).
8. Woo, E.J., Winiacki, S.K. & Ou, A.C. Motor palsies of cranial nerves (excluding VII) after vaccination: reports to the US Vaccine Adverse Event Reporting System. *Hum Vaccin Immunother* **10**, 301-305 (2014).
9. Xia, X. Detailed Dissection and Critical Evaluation of the Pfizer/BioNTech and Moderna mRNA Vaccines. *Vaccines (Basel)* **9**(2021).
10. Barry, R.C., *et al.* Interventional treatment of carotid cavernous fistula. *J Clin Neurosci* **18**, 1072-1079 (2011).